

See discussions, stats, and author profiles for this publication at: <https://www.researchgate.net/publication/257657389>

Intrathecal Autologous Bone Marrow Mononuclear Cell Transplantation in a Case of Adult Autism

Article in *Autism Open Access* · September 2013

DOI: 10.4172/2165-7890.1000113

CITATIONS

7

READS

135

7 authors, including:



Alok Sharma

Jubilant Life Sciences

151 PUBLICATIONS **1,916** CITATIONS

SEE PROFILE



Hemangi Sane

Neurogen Brain and Spine Institute

26 PUBLICATIONS **154** CITATIONS

SEE PROFILE



Pooja Kulkarni

Neurogen Brain and Spine Institute

24 PUBLICATIONS **187** CITATIONS

SEE PROFILE



Amruta Paranjape

Neurogen Brain and Spine Institute

16 PUBLICATIONS **114** CITATIONS

SEE PROFILE

Case Report

Open Access

Intrathecal Autologous Bone Marrow Mononuclear Cell Transplantation in a Case of Adult Autism

Alok Sharma¹, Nandini Gokulchandran¹, Hemangi Sane², Pooja Kulkarni^{2*}, Nancy Thomas³, Amruta Paranjape³ and Perna Badhe¹

¹Department of Medical Services and Clinical Research, NeuroGen Brain and Spine Institute, India

²Department of Research and Development, NeuroGen Brain and Spine Institute, India

³Department of Neuro Rehabilitation, NeuroGen Brain and Spine Institute, India

Abstract

Autism is a complex neurodevelopmental disorder with a worldwide prevalence of 1 in 88. With greater understanding of mechanism of action of cellular therapy it is now possible to address the pathogenesis of autism. Recent findings of cellular therapy offering immunomodulatory, angiogenic and paracrine effects make it a lucrative option for treatment of autism. We administered a 33 year old adult patient of autism intrathecally, with autologous bone marrow mononuclear cells (BMMNCs), twice with an interval of six months. On follow up at 3, 6 and 9 months post first intervention, he was re-evaluated clinically and no major or minor side effects were observed. At 6 and 9 months objective outcome measures of Indian Scale for Assessment of Autism (ISAA) and Clinical Global Impression (CGI) were used and they showed significant improvement. At the end of 9 months, on ISAA, the score improved from 94 to 64. The CGI showed improvement by change in severity of illness from 3 (Mildly ill) to 1 (Borderline mentally ill). Global improvement on CGI was scored 2 (much improved) with an efficacy index of 5 (moderate therapeutic effect). PET CT scan was repeated at 6 months which showed a balancing effect in the metabolism of affected areas. The changes observed on the PET CT scan correlated with clinical improvements. MRI remained same at 6 months thereby, indicating that PET CT scan may serve as a better monitoring tool for effects of cellular therapy. In this case study, we hypothesize that cellular therapy has repaired the neural connections and achieved balance in the excitatory and inhibitory neuronal cells by various mechanisms of neuroprotection, neuromodulation and neurorestoration. Cell therapy holds great potential and randomized controlled trials may be conducted to study their long term effects in treating autism.

Keywords: Autism; Cellular therapy; Autologous; Bone marrow mononuclear cells; PET CT

Introduction

Autism is a neurodevelopmental condition with cognitive and neurobehavioral issues leading to impairments in socialization, verbal and non-verbal communication and behavior. The symptoms are noticed at around twelve–eighteen months. However, at times autism is diagnosed at adulthood [1]. The prevalence of autism is estimated to be about 1 in 88 [2]. Adults with autism are deprived of social relationships, employment and a better quality of life [3]. Development of effective interventions is thus required to help the amalgamation of these adult patients into the wider society.

All the present available treatments for autism are targeted towards specific symptoms. Cell therapy as a treatment for autism is currently being explored. Adult stem cells have shown positive benefits in various neurological disorders such as cerebral palsy, stroke, etc [4,5]. Various mechanisms have known to be responsible for the positive effect of cellular therapy which include a combination of trophic factor delivery, neuroplasticity, neuromodulation, neuroprotection, angiogenesis amongst others [6]. With an aim to further study the effect of cell therapy in adult autism, we administered an adult patient of autism with autologous bone marrow mononuclear cells (BMMNCs), twice at an interval of six months. To our knowledge, there is no published case study of cell therapy in adult autism. Thus, this case report provides an insight of application of cell therapy in adult autism.

Case Report

Case presentation

A thirty three years old male was diagnosed with autism at the age of eighteen years. He achieved normal motor milestones except speech.

His speech developed only after the age of three years. At six to eight years of age, hyperactivity developed along with behavioral issues like laughing without reason, hitting others, poor eye contact and running without reason. By the age of fourteen he became more aggressive and started showing temper tantrums and poor social interaction skills. Responses were delayed due to which he required repetitive commands. At the age of eighteen years he was diagnosed as autism. He lacked empathy, had difficulty understanding other person's feelings. There was a failure to establish relationships including sexual relationships. Absence of understanding of making a family. Since the age of eighteen he underwent rehabilitation including behavior therapy, occupational therapy and speech therapy. He was trained to become independent in activities of daily living. Vocational rehabilitation was provided, so he could stitch, make boxes and work on a computer. Presently, his eye contact and social interaction was affected. He stayed aloof and did not maintain peer relationships. Emotional responses were also poor. He used stereotyped and repetitive language. Behavior was aggressive and he threw temper tantrums.

***Corresponding author:** Pooja Kulkarni, Department of Research and Development, NeuroGen Brain and Spine Institute, Surana Sethia Hospital and Research Centre, Mumbai-400071, India, Tel: +9122-25281610/ +9122-25283706; E-mail: poojakul28@gmail.com

Received June 25, 2013; **Accepted** September 01, 2013; **Published** September 06, 2013

Citation: Sharma A, Gokulchandran N, Sane H, Kulkarni P, Thomas N, et al. (2013) Intrathecal Autologous Bone Marrow Mononuclear Cell Transplantation in a Case of Adult Autism. Autism 3: 113. doi:10.4172/2165-7890.1000113

Copyright: © 2013 Sharma A, et al. This is an open-access article distributed under the terms of the Creative Commons Attribution License, which permits unrestricted use, distribution, and reproduction in any medium, provided the original author and source are credited.

Pre-intervention assessment

MRI brain showed mild cerebral and cerebellar atrophy. The EEG showed no epileptogenic focus. On Indian Scale for Assessment of Autism (ISAA) he scored 94 (mild autism with 60% disability). On Clinical Global Impression (CGI) scale, severity of illness (CGI-I) was scored 3 which was mildly mentally ill. PET CT scan was performed using the Siemens Biographmct with 64 slice high speed scanner- 3D PET True V wide detector (Siemens-CTI, Knoxville, Tenn., USA), with a resolution of 0.6-mm full width at half maximum (FWHM) and the images of 45-50 contiguous transverse planes with a field of view of 21.6 cm axial PET FOV with True V (Figure 1). The mean standardized uptake values (SUV) are given in the Table 1.

Isolation and administration of autologous bone marrow mononuclear cells

The protocol is based on the inclusion criterion as per the World Medical Associations Helsinki declaration [7]. It has been reviewed and approved by the Institutional committee for Stem cell Research and Therapy (IC-SCRT). The patient's parents were informed about the procedure and a duly filled informed consent form was obtained. 300 mcg of G-CSF injections were administered 48 hours and 24 hours before bone marrow derived mononuclear cell transplantation, to stimulate CD34+ cells and increase their survival and multiplication. Bone marrow (100 ml) was aspirated from the anterior superior iliac crest bone using the bone marrow aspiration needle. Mononuclear cells (MNCs) were obtained from the bone marrow by density gradient separation method. Viable count of the isolated MNCs was taken and was found to be about 98%. The MNCs were checked for CD34+ by FACS analysis. Approximately 56×10^6 MNCs were immediately injected post separation, intrathecally at L4-L5 level using an 18G Touhy needle and epidural catheter. Simultaneously, the patient was administered with one dose of 30 mg/kg methylprednisolone intravenously.

Neurorehabilitation

The patient was also given multidisciplinary therapies which included occupational therapy, psychological therapy, applied behavior analysis, sensory integration and speech therapy. It included Vestibular activities like tandem walking, peg transfers on vestibular board/swiss ball etc, kneel walking, ball throwing in standing etc, therapeutic activities like grouping, sequencing, improving eye hand coordination and visual perceptual skills were included. Social interaction and skills were emphasized during the therapy sessions. During his psychological

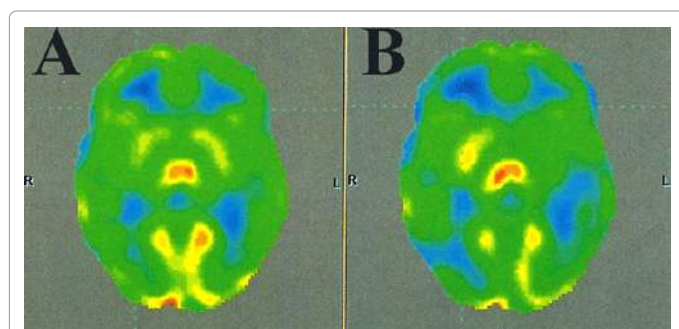


Figure 1: (A) PET CT scan of the patient carried out before cell therapy, (B) PET CT scan of the patient carried out after cell therapy. Comparison of PET CT scans demonstrating improvements after cell therapy i.e., the yellow areas decreased in the post intervention scan as indicated by SUV values in Table 1.

Areas	Mean SUV (PRE)	Mean SUV (POST)	Correlating clinical functional improvements observed in the case
Frontal Lobe Left	6.86	5.85	initiation, planning, anticipation, organization, problem solving, emotions, attention
Frontal Lobe Right	6.92	5.67	
Cingulate and Paracingulate gyri Left	6.72	5.57	Social brain processing
Cingulate and Paracingulate gyri Right	6.62	5.39	
Temporal Left	6.84	5.44	Social Interaction, memory and categorizing objects
Temporal Right	6.95	5.85	
Mesial Temporal Left	4.96	4.01	Social brain processing
Mesial Temporal Right	5.34	4.48	
Middle Cingulate Left	7.23	5.88	emotion processing, learning and memory
Middle Cingulate Right	7.31	5.95	
Amygdala Left	4.7	3.97	emotions, memory, social interaction, behavior
Amygdala Right	4.85	4.18	
Hippocampus Left	4.49	3.77	social interaction
Hippocampus Right	4.58	3.97	
Para hippocampus Left	5.47	4.25	Scene recognition and social context
Para hippocampus Right	6.08	4.97	
Parietal lobe Left	6.69	5.7	integration of sensory information and language
Parietal lobe Right	6.49	5.3	
Posterior cingulate Left	6.71	5.76	emotional and motor tasks
Posterior cingulate Right	5.78	4.24	
Anterior cingulate Left	6.03	5.07	attention, motivation, anticipation of tasks, emotional responses
Anterior cingulate Right	5.69	4.76	
Basal Ganglia Left	7.63	5.71	voluntary movement, coordination
Basal Ganglia Right	7.73	6.7	
Cerebellum Left	6.08	5.4	Coordination, memory, emotions
Cerebellum Right	5.6	4.56	

Table 1: Comparison of pre and post intervention SUV values in 18 FDG PET CT scan and correlation with clinical symptom improvement in the case study.

sessions, cognitive rehabilitation, family counseling and psychological education was emphasized.

Outcome measures used

On follow up at three, six and nine months post first intervention, he was re-evaluated clinically and no major or minor side effects were observed. At six and nine months objective outcome measures of ISAA and CGI were used. PET CT scan was repeated at six months after the intervention.

Results

After the procedure, the patient had no major or minor side effects. There was improvement in eye contact within a week. After three months of follow up, reduction in hyperactivity and reduced repetitive speech was observed. On six months follow up, improvements further continued. Attention span increased along with decrease in temper tantrums. His tongue movements improved and he could eat without spilling due to improved eye-hand coordination. Reduction in the behavioral issues such as self- talking, laughing loudly was also noted. He was reassessed on ISAA scale wherein the score reduced from 94 (Mild autism with 60% disability) to 79 (Mild autism with 50% disability). On ISAA, he improved in language and communication, behavior pattern and sensory aspects (Table 2). On repeating his PET CT scan after six months, it was observed that various areas of brain showed reduction in FDG uptake (Table 1). MRI of the brain

	Sub-components of ISAA	Score Pre treatment	Score at 6 month follow up	Score at 9 month follow up
A.	Social Relationship and Reciprocity	30	30	17
1	Poor Eye contact	5	3	1
2	Lacks social smile	5	5	1
3	Remains aloof	5	5	4
4	Does not reach out to others	2	2	1
5	Unable to take turns in social interaction	4	4	3
6	Does not maintain peer relationships	4	4	2
B.	Speech Language and Communication	14	13	11
1	Engages in stereotyped and repetitive use of language	5	3	2
2	Unable to initiate or sustain conversation with others	3	3	1
3	Unable to grasp pragmatics of communication (real meaning)	5	1	1
C.	Behaviour Patterns	18	13	13
1	Shows hyperactivity and restlessness	4	3	3
2	Exhibits aggressive behavior	5	3	3
3	Throws temper tantrums	5	3	3
D.	Sensory Aspects	12	9	7
1	Stares into space for long periods of time	4	3	2
2	Has unusual vision	4	2	1

Table 2: Table giving details of the improvements in different sub components on ISAA at follow up of 3 months and 18 months.

remained same after six months. With a purpose of sustaining these improvements he underwent a second dose of autologous BMMNCs at six months after the first intervention. Three months after the second cell therapy, (nine months after the first intervention) hyperactivity and aggressive behavior further reduced drastically. Eye contact along with repetitive speech had improved. His problem solving and response time had reduced as he could solve mathematical problems and he could answer faster. His ISAA further reduced to 64 (no autism). On Clinical Global Impression (CGI) scale, his severity of illness (CGI-I) before the first intervention was 3 (mildly ill) while nine months after the therapy it was 2 (borderline mentally ill). The global improvement (CGI-II) was rated 2 (much improved) and efficacy index (CGI-III) was 5 (moderate improvement with no side effects).

Discussion

Autism, a complex neurodevelopmental condition, is caused by atypical brain development beginning during early prenatal or postnatal life. The underlying pathophysiologic mechanism in autism is still being explored. Currently, various mechanisms are postulated for pathogenesis of autism. Evidence suggests that immune dysfunction is associated with impairment in behavior, deficit in social interaction and communication. It involves increased cytokine production which inhibits neurogenesis and leads to neuronal death along with inflammation in brain. There is an increase in brain specific autoantibodies and altered immune cell function [8].

Some studies suggest that the imbalance in inhibition-excitation of neurons has a direct impact on the adult brain plasticity and is the foundation of the pathogenesis of neurodevelopmental disorders like autism [9]. Elevated levels of excitation could be due to increased glutamatergic transmission or suppressed GABAergic inhibition. Suppressed GABAergic inhibition thus could be one of the etiologies of autism [10]. Cortical interneurons make up to 20% of the cells in cortex. These cells modulate the firing activities of the excitatory projection neurons. The dysfunction of cortical interneurons is also believed

to be the underlying pathophysiology of autism [11]. Neuroimmune abnormalities may be reflected as neuroglial activation in the brain [12]. Suzuki et al. [13] in their recent study, have indicated excessive microglial activation in multiple brain regions in young adult subjects with ASD.

Neuroanatomical studies suggest that frontal lobes, mesial temporal lobe (especially amygdala) and cerebellum are also involved in the pathology of autism [14]. In a multicentre study conducted on adult men with autism, it was found that there is a significant increase in gray matter volume in the anterior temporal and dorsolateral prefrontal regions along with significant reduction in the occipital and medial parietal regions as compared to the control group [15]. Brain volume in the frontal lobes is larger, whereas the occipital lobes are smaller in size in individuals with autism [16]. On studying the brain function of language processing in children and adults with autism it was found that left middle temporal, left pars triangularis, left pars opercularis, left medial frontal, and right middle temporal were the most affected. The autism group differed from the control group in the degree of network coordination and the dynamic recruitment of regions in response to stimulus [17]. All the above findings are observed in some patients with autism. In autism, the trajectory of brain development is more disturbed.

Many treatment options have been studied for adults and children with autism such as behavioral and developmental interventions, vocational therapy, pharmacotherapy, etc [18,19]. Vocational therapy and other rehabilitation interventions alone have not shown desirable benefits in adolescents and young adults with autism [20]. Medications are used to treat the comorbid conditions such as anxiety, seizures, depression and not the core symptoms of autism [21]. Since 2006, few drugs have been approved by the FDA. But, adverse events including weight gain, sedation and increased risk of mortality among adults have been recorded with use of these drugs [22].

In neurological disorders, it has been observed that stem cells improve the damaged neuronal function which is also one of the underlying pathogenetic mechanisms of autism [23]. With an aim to study the benefits of stem cells in autism, we transplanted autologous BMMNCs in an adult with autism. Bone marrow cells are safe and are widely available with no ethical or carcinogenic issues involved as compared to embryonic/fetal cells. BMMNCs are a mixed population of differentially matured B-cells, T-cells and monocytes, along with progenitor cells such as hematopoietic stem cells (HSC), mesenchymal stromal cells (MSC), endothelial progenitor cells (EPC) and very small embryonic-like cells (VSEL) [24]. It has been observed that the whole BMMNCs are more effective compared to the fractionated parts [25]. Studies suggest that these cells improve oxygenation, as they reduce the brain hypoperfusion by stimulating angiogenesis. BMMNCs can modulate the immune system by inhibiting the proliferation of CD3+, CD4+, CD8+ T cells and NK cells [26]. The transplanted cells migrate and home onto the damaged areas of the brain and produce factors such as VEGF, BDNF, FGF2, activating the endogenous repair mechanism and contributing to recovery of lost neuronal function [27,28].

The intervention is safe as being autologous; the cells evade the possibility of any reaction. Intrathecal administration of cells is a relatively less invasive procedure. These cells migrate via the CSF to the affected areas in the brain. The transplanted cells home into the damaged sites by crossing the blood brain barrier. It has been seen that various mechanisms including inflammation alters the permeability of the blood brain barrier in autism [29,30]. In this case study, after autologous BMMNC transplantation we observed significant

improvements in social relationship, behavior along with language and communication. On correlating these improvements, it can be assumed that there was improvement in temporal, amygdala and Wernicke's area of the brain.

PET CT scan was used as a monitoring tool. It is a non-invasive and a relatively safe functional neuroimaging technique which examines the association between the metabolic activity in the brain and the mental processes. The 18-FDG dye used for the PET CT scan is an analogue of glucose which provides functional information of the cells based on the glucose uptake [31]. Reduced glucose uptake reflects reduced metabolic activity of those brain cells. The standardized uptake value (SUV) is used as a relative measure of FDG uptake [32]. These values are compared to a normal controlled SUV and a standard deviation (SD) value is calculated which indicates the areas of the brain functioning beyond the normal limits. Hence, the hyperfunctioning areas of the brain will show hypermetabolism and hypofunctioning areas will show hypometabolism. A reduction in hyperfunctioning areas or increase in hypofunctioning areas may reflect as a clinical functional improvement. In our case, on correlating the clinical improvements to the specific areas of the brain we observed a reduction in metabolism of these particular areas after the intervention. Therefore, the reduction in metabolism is a positive indicator of clinical functional improvement (Table 1). Since, the decrease in SUV values corresponds to the clinical improvements, we may hypothesize that the reduction in metabolism has restored the function of neurons. After six months, the PET CT scan recorded changes corresponding with the clinical improvements while the MRI showed no change. Hence, PET CT scan was more sensitive to study the effect of intervention as compared to the MRI.

One of the limitations of this case report is that there is no control to compare the effect of intervention, but we can consider the case as self control due to the age of the patient and his static condition despite of regular rehabilitation pre intervention. Also, for the PET CT scan, the SUV values of the normal adults (control) were not available as it was a computerized program and the values were automatically generated and compared by the software and reported as SD values. The control group values are for normal adult population and there is a need to study and gather baseline values for autism population.

We hypothesize that cellular therapy has stimulated repair processes of the neural connections and achieved balance in the excitatory and inhibitory neuronal cells by various mechanisms of neuroprotection, neuromodulation and neurorestoration. Cell therapy holds a great potential and randomized controlled trial may be conducted to study their long term effects in treating adults with autism.

References

1. Filipek PA, Accardo PJ, Baranek GT, Cook EH Jr, Dawson G, et al. (1999) The screening and diagnosis of autistic spectrum disorders. *J Autism Dev Disord* 29: 439-484.
2. Autism and Developmental Disabilities Monitoring Network Surveillance Year 2008 Principal Investigators; Centers for Disease Control and Prevention (2012) Prevalence of autism spectrum disorders—Autism and Developmental Disabilities Monitoring Network, 14 sites, United States, 2008. *MMWR Surveill Summ* 61: 1-19.
3. Piven J, Rabins P (2011) Autism-in-Older Adults Working Group. Autism spectrum disorders in older adults: toward defining a research agenda. *J Am Geriatr Soc* 59: 2151-2155.
4. Sharma A, Gokulchandran N, Chopra G, Kulkarni P, Lohia M, et al. (2012) Administration of autologous bone marrow derived mononuclear cells in children with incurable neurological disorders and injury is safe and improves their quality of life. *Cell Transplantation* 21: S1-S12.
5. Bhasin A, Padma Srivastava MV, Mohanty S, Bhatia R, Kumaran SS, et al (2013) Stem cell therapy: A clinical trial of stroke. *Clin Neurol Neurosurg* 115: 1003-1008.
6. Huang H, Chen L, Sanberg P (2010) Cell Therapy From Bench to Bedside Translation in CNS Neurorestoration Era. *Cell Med* 1: 15-46.
7. Carlson RV, Boyd KM, Webb DJ (2004) The revision of the Declaration of Helsinki: Past, present and future. *Br.J. Clin. Pharmacol* 57: 695-713.
8. Onore C, Careaga M, Ashwood P (2012) The role of immune dysfunction in the pathophysiology of autism. *Brain Behav Immun* 26: 383-392.
9. Baroncelli L, Braschi C, Spolidoro M, Begenisic T, Maffei L, et al. (2011) Brain plasticity and disease: a matter of inhibition. *Neural Plast.*
10. Ben-Ari Y, Khalilov I, Kahle KT, Cherubini E (2012) The GABA excitatory/inhibitory shift in brain maturation and neurological disorders. *Neuroscientist* 18: 467-486.
11. Arber C, Li M (2013) Cortical interneurons from human pluripotent stem cells: prospects for neurological and psychiatric disease. *Front Cell Neurosci* 7: 10.
12. Morgan JT, Chana G, Pardo CA, Achim C, Semendeferi K, et al. (2010) Microglial activation and increased microglial density observed in the dorsolateral prefrontal cortex in autism. *Biol Psychiatry* 68: 368-76.
13. Suzuki K, Sugihara G, Ouchi Y, Nakamura K, Futatsubashi M, et al. (2013) Microglial activation in young adults with autism spectrum disorder. *JAMA Psychiatry* 70: 49-58.
14. Amaral DG, Schumann CM, Nordahl CW (2008) Neuroanatomy of autism. *Trends Neurosci* 31: 137-145.
15. Ecker C, Marquand A, Mourao-Miranda J, Johnston P, Daly EM, et al (2010) Describing the brain in autism in five dimensions-magnetic resonance imaging-assisted diagnosis of autism spectrum disorder using a multiparameter classification approach. *J Neurosci* 30: 10612-10623.
16. Philip RC, Dauvermann MR, Whalley HC, Baynam K, Lawrie SM, et al. (2012) A systematic review and meta-analysis of the fMRI investigation of autism spectrum disorders. *Neurosci Biobehav Rev* 36: 901-942.
17. Williams DL, Cherkassky VL, Mason RA, Keller TA, Minshew NJ, et al. (2013) Brain Function Differences in Language Processing in Children and Adults with Autism. *Autism Res.*
18. Doyle CA, McDougle CJ (2012) Pharmacotherapy to control behavioral symptoms in children with autism. *Expert Opin Pharmacother* 13: 1615-1629.
19. Taylor JL, McPheeters ML, Sathe NA, Dove D, Veenstra-Vanderweele J, et al. (2012) A systematic review of vocational interventions for young adults with autism spectrum disorders. *Pediatrics* 130: 531-538.
20. Ospina MB, Krebs Seida J, Clark B, Karkhaneh M, Hartling L, et al. (2008) Behavioural and developmental interventions for autism spectrum disorder: a clinical systematic review. *PLoS One* 3.
21. Dove D, Warren Z, McPheeters ML, Taylor JL, Sathe NA, et al. (2012) Medications for adolescents and young adults with autism spectrum disorders: a systematic review. *Pediatrics* 130: 717-726.
22. Maher AR, Theodore G (2012) Summary of the comparative effectiveness review on off-label use of atypical antipsychotics. *J Manag Care Pharm* 18: S1-S20.
23. Blurton-Jones M, Kitazawa M, Martinez-Coria H, Castello NA, Muller FJ, et al. (2009) Neural stem cells improve cognition via BDNF in a transgenic model of Alzheimer disease. *Proc Natl Acad Sci USA* 106: 13594-13599.
24. Pösel C, Möller K, Fröhlich W, Schulz I, Boltze J, et al. (2012) Density Gradient Centrifugation Compromises Bone Marrow Mononuclear Cell Yield. *PLoS one* 7.
25. Krebsbach PH, Kuznetsov SA, Bianco P, Robey PG (1999) Bone marrow stromal cells: characterization and clinical application. *Crit Rev Oral Biol Med* 10: 165-181.
26. Hoogduijn MJ, Popp F, Verbeek R, Masoodi M, Nicolaou A, et al. (2010) The immunomodulatory properties of mesenchymal stem cells and their use for immunotherapy. *Int Immunopharmacol* 10: 1496-1500.
27. Meirelles Lda S, Fontes AM, Covas DT, Caplan AI (2009) Mechanisms involved

- in the therapeutic properties of mesenchymal stem cells. *Cytokine and Growth Factor Rev* 20: 419-427.
28. Baraniak PR, McDevitt TC (2010) Stem cell paracrine actions and tissue regeneration. *Regen Med* 5: 121-143.
29. Theoharides TC, Angelidou A, Alysandrat KD, Zhang B, Asadi S, et al (2012) Mast cell activation and autism. *Biochim Biophys Acta* 1822: 34-41.
30. Theoharides TC, Zhang B (2011) Neuro-inflammation, blood-brain barrier, seizures and autism. *J Neuroinflammation* 30: 168.
31. Almuhaideb A, Papathanasiou N, Bomanji J (2011) 18F-FDG PET/CT imaging in oncology. *Ann Saudi Med* 31: 3-13.
32. Thie JA (2004) Understanding the standardized uptake value, its methods, and implications for usage. *J Nucl Med* 45: 1431-1434.

Citation: Sharma A, Gokulchandran N, Sane H, Kulkarni P, Thomas N, et al. (2013) Intrathecal Autologous Bone Marrow Mononuclear Cell Transplantation in a Case of Adult Autism. *Autism* 3: 113. doi:[10.4172/2165-7890.1000113](https://doi.org/10.4172/2165-7890.1000113)

Submit your next manuscript and get advantages of OMICS Group submissions

Unique features:

- User friendly/feasible website-translation of your paper to 50 world's leading languages
- Audio Version of published paper
- Digital articles to share and explore

Special features:

- 250 Open Access Journals
- 20,000 editorial team
- 21 days rapid review process
- Quality and quick editorial, review and publication processing
- Indexing at PubMed (partial), Scopus, EBSCO, Index Copernicus and Google Scholar etc
- Sharing Option: Social Networking Enabled
- Authors, Reviewers and Editors rewarded with online Scientific Credits
- Better discount for your subsequent articles

Submit your manuscript at: <http://www.omicsonline.org/submission/>

