

## Case Report

---

# Cell therapy effects portrayed on positron emission tomography of the brain serve as a new dimension for autism

Alok Sharma<sup>a</sup>, Nandini Gokulchandran<sup>a</sup>, Hemangi Sane<sup>b</sup>, Pradnya Bhovad<sup>a,\*</sup>, Hema Bijuc<sup>c</sup>, Akshata Shetty<sup>c</sup>, Mrudula Kali<sup>c</sup> and Prerna Badhe<sup>a</sup>

<sup>a</sup>*Department of Medical Services and Clinical Research, NeuroGen Brain and Spine Institute, Mumbai, India*

<sup>b</sup>*Department of Research and Development, NeuroGen Brain and Spine Institute, Mumbai, India*

<sup>c</sup>*Department of Neurorehabilitation, NeuroGen Brain and Spine Institute, Mumbai, India*

Received 23 October 2013

Revised 22 January 2014

Accepted 31 January 2014

**Abstract.** Cell therapy offers a promising premise in alleviating complex neurological disorders. Autologous bone marrow mononuclear cells (BMMNCs) have been used in many studies and have been documented to have a safe and ethical profile. These cells have shown angiogenic and immunomodulatory properties in addition to other neuroprotective effects. Precisely, these may serve to address a disorder at a neurophysiological level and thus, hold gratifying results in autism. The literature suggests hypoperfusion and immune alteration as major underlying pathogenetic mechanisms in autism. Herewith, we present a case of autism treated with intrathecal administration of autologous BMMNCs. Results were documented objectively on Indian Scale for Assessment of Autism (ISAA), Childhood Autism Rating Scale (CARS), Clinical Global Impression (CGI) scores and positron emission tomography computerized tomography (PET-CT) scan. On regular follow-up assessment of the patient at 3 mo, at 6 mo (pre 2nd dose) and at 9 mo (i.e., 3 mo post 2nd dose), significant clinical improvement was noted in social relationship, communication and behavior. On the outcome measure, his ISAA score improved from 132 (moderate autism) to 103 (mild autism). On comparison of the PET-CT scan, changes in metabolism correlated with the clinical improvements. On the CGI scores, he showed improvement in all the three domains, with a decrease in the severity of illness and with partial remission of symptoms. This case provides a useful insight into the clinical effects of autologous BMMNCs in autism and guides us to plan future studies and offers a promising premise in alleviating complex neurological disorders.

**Keywords:** Autism, autologous, bone marrow, stem cells, stem cell therapy, mononuclear cells

## 1. Introduction

Autism is one of the fastest growing neurodevelopmental disorders that affect the entire social reper-

toire of a child. It is classically manifested by impaired social interaction, communication difficulties, and restricted, repetitive, and stereotyped patterns of behavior [1]. Of these, the most significant impairments are in communication and social behavior [2]. These patterns result in increased difficulty in establishing and maintaining routines and marked difficulties in social and occupational functioning. Autism or

---

\*Correspondence: Dr. Pradnya Bhovad, Occupational Therapist, NeuroGen Brain and Spine Institute, Surana Sethia Hospital and Research Centre, Suman Nagar, Sion-Trombay Road, Chembur, Mumbai, 400071, India. Tel.: +91 22 25281610/25283706; Fax: +91 25288808; E-mail: publications@neurogen.in.

classical autism spectrum disorder (ASD) is the most severe form of ASD while other conditions along the spectrum include a milder form known as Asperger syndrome, childhood disintegrative disorder and pervasive developmental disorder not otherwise specified (PDD-NOS). Although ASD varies significantly in character and severity, it occurs in all ethnic and socioeconomic groups and affects every age group with a definite male preponderance. Early screening and multidisciplinary intervention can alleviate the distressing behavioral patterns classically associated with autism but do not address the pathology at the molecular level.

Cell therapy is explored as a potential treatment alternative for autism. A combination of paracrine mechanisms such as release of tropic factors, angiogenesis, neuroplasticity, neuromodulation, neuroprotection, etc., are known to be responsible for the positive therapeutic outcome of cell therapy [3]. Paracrine mechanisms of the cell-based therapy have been found to be responsible for immune modulation and ischemic tissue repair [3]. In addition, cell-based therapy consisting of CD34+ cells has been found to have an essential role in promoting directly or indirectly an environment conducive to neovascularization and angiogenesis in animal models. To study this further, a case of autism treated with autologous bone marrow mononuclear cells (BMMNCs) has been put forth below.

## 2. Case report

Herewith we present a case of a 9-year-old male diagnosed with autism. His prenatal history was insignificant except for the fact that the mother had experienced mental stress during first and second trimesters of pregnancy. As per his natal history, he was born full term normal delivery and cried immediately after birth. Postnatal history was reported to have neonatal jaundice with phototherapy given for 3 d. Motor milestones were grossly age appropriate. Delayed social milestones such as the presence of bi-syllable speech till the age of 2.5 yr were reported. There were poor eye contact and presence of persistent repetitive behavior in the form of repetitive flapping of hands and poor social interaction with hyperactive behavior. Brainstem evoked response audiometry report was normal. The parents consulted a special educator and a psychiatrist who both diag-

nosed him with autism. He was reported to be dependent for all his activities of daily living (ADLs). Electroencephalography report was found to be abnormal with background rhythm consisting of alpha to theta wave pattern and presence of bilateral generalized sharp wave discharges. Magnetic resonance imaging scan of the brain was normal. Positron emission tomography computerized tomography (PET-CT) scan of the brain revealed a reduction in the standardized [(18)F]-fluoro-2-deoxy-D-glucose uptake values in the mesial temporal structures, cerebellar hemispheres, hippocampus, amygdala and parahippocampalgyrus. On the other hand, there was an increase in the standardized [(18)F]-fluoro-2-deoxy-D-glucose uptake values seen in the frontal, parietal and occipital lobes. He underwent comprehensive rehabilitation consisting of occupational therapy, speech therapy and psychological interventions. In spite of these standard procedures, no significant improvement was noted. Hence, he was considered for stem cell therapy with an aim to address the core underlying neurophysiological and neurochemical mechanism of autism.

The patient underwent intrathecal administration of autologous BMMNCs. The inclusion criterion was as per the world medical associations Helsinki declaration, and the protocol procedure used was approved by the institutional committee for stem cell research and therapy. A duly filled informed consent document was obtained after explaining the procedure in detail to the patient's parents. He was assessed pre-cell therapy on functional independence measure, childhood autism rating scale (CARS) and Indian Scale for the Assessment of Autism (ISAA) outcome measures as well as magnetic resonance imaging (MRI) scan and PET-CT scan of the brain were done. 300 µg of granulocyte colony stimulating factor injections were administered 48 h and 24 h before bone marrow derived mononuclear cell transplantation to stimulate CD34+ cells and increase their survival, viability and multiplication. 100 mL of bone marrow was aspirated from the anterior superior iliac bone using a pediatric bone marrow aspiration needle and was collected in heparinized tubes. Mononuclear cells were obtained using density gradient separation method and were 98% viable. The cell count of  $9.6 \times 10^7$  was obtained. These cells were immediately injected intrathecally in L4-L5 using a lumbar puncture needle. The CD34+ count was analyzed using the fluorescence activated cell-sorting method and was found to be 1.64. Methyl-

Table 1  
Comparison of pre cell therapy and post cell therapy scores

Outcome measures	Pre-cell therapy	Postcell therapy 3 mo	Postcell therapy 6 mo
Childhood Autism Rating Scale score	38	31	26
Indian Scale for the Assessment of Autism score	132	108	103
Functional Independence Measure score	84	84	84

Table 2  
Summary of clinical global impression scores

Clinical global impression scores	Pre-cell therapy	Postcell therapy 3 mo	Postcell therapy 6 mo
Severity of illness	5 (markedly ill)	4 (moderately ill)	4 (moderately ill)
Global improvement	Not available	2 (much improved)	2 (much improved)
Efficacy index	Not available	5 (decided improvement with partial remission of symptoms)	5 (decided improvement with partial remission of symptoms)

prednisolone (500 mg in 500 mL ringer lactate) was given intravenously (simultaneously) during cell transplantation for the first time. Post-stem cell therapy, comprehensive rehabilitation including occupational therapy and neuropsychological counseling was provided with an emphasis on home program. The occupational therapy session was designed to address his sensory modulation issues of vestibular, proprioceptive and tactile systems through numerous activities as well as activities to improve eye contact, attention span, fine motor coordination, motor imitation and projected action sequences. Psychological interventions included cognitive rehabilitation, play therapy, family counseling and behavior modification techniques along with speech therapy. After 6 mo from the date of first cell therapy, he underwent cell transplantation for the second time, wherein the total cell count was  $1.2 \times 10^8$  and the viability of the cells was 98%. The CD34+ count analyzed using the fluorescence-activated cell sorting method was 5.16. The CD34+ count during the 1<sup>st</sup> cell transplantation was 1.64 and during the second cell transplantation was 2.58.

The patient was followed up for 9 mo after cell therapy. Immediate improvements were reported within a week after the therapy. No minor or major adverse events related to procedure or cell transplantation were reported. Parents reported that his command following had improved. His hyperactive behavior had decreased and his eye contact was better as compared to his baseline evaluations. At 3 mo of follow-up, command following had improved along with his attention span and projected action sequences. Response to name following had also improved as well as his participation in age appropriate ADLs had

improved. Reaction time had improved. Inappropriate smiling and laughter had also reduced. Parents also reported a decrease in repetitive behavior, and also his fear of heights had decreased. After 6 mo, he underwent cell therapy for the second time, and further improvements were noted by the parents. Modulating emotional responses as per social and environmental cues and verbal instructions could be performed with better ease and lesser verbal instructions. Repetitive behavior in form of teeth grinding had stopped almost completely. Level of understanding was reported to be improved. Improvement in gait pattern was also noted, and walking on toes was reported to have stopped almost completely. On comparison on the scales, his ISAA score showed improvement from 132 (moderately autistic) to 103 (mildly autistic), wherein more improvement was noted on the continuum of social relationships and reciprocity, emotional responsiveness and behavior patterns along with cognitive component. This was followed by a subsequent improvement in the sensory aspects and speech language communication. This correlation was also seen on the CARS, wherein an improvement was seen from a score of 31 (moderately autistic) to 26 (non-autistic). Noteworthy areas of improvement were social relationships, modulation of emotional responses, overall activity levels and skilled object use and manipulation as put forth in Tables 1 and 2.

### 3. Discussion

In our patient, CGI 1 (severity of illness) scores showed improvement both at 3rd and 6th mo follow-ups from markedly ill to moderately ill. His severity of

Table 3

Summary of changes as observed on PET CT scan of brain in pre-cell therapy and post cell therapy along with the clinical co-relation

Areas improved in PET CT scan (as observed in pre and post PET CT scan)	SD precell therapy	SD 6 mo postcell therapy	SUV precell therapy	SUV 6 mo after first cell therapy	Clinical improvements observed in the patient's pertaining areas
Parahippocampal gyrus (Lt)	-5.0	-2.5	2.47	3.85	Involved in visuo-spatial processing leading to improvement in projected action sequences and object manipulation
Hippocampus (left)	-8.9	-7.7	2.14	3.07	Involved in memory responses resulting in improved emotional responses
Mesial temporal structures (left)	-6.9	-5.1	2.31	3.43	Involved in apparent modulation behaviour responses
Cingulate and paracingulate gyrus (left)	3.2	1.5	4.67	5.77	Involved in cognitive responses and general arousal
Cingulate and paracingulate gyrus (right)	2.8	1.4	4.42	5.54	Involved in cognitive responses and general arousal
Temporal lobe (right)	2.5	1.6	4.53	5.89	Involved in language comprehension and social interaction

SD = Standard deviation; SUV = Standard uptake value; PET = Positron emission tomography; CT = Computerized tomography.

illness had reduced at the 3 mo follow-up as compared to pre-cell therapy. Along with this, on the CGI 2 (global improvement) and CGI 3 (efficacy index) sustained improvement at 3<sup>rd</sup> mo and at 6th mo follow-up. On the CGI 3, there was decided improvement of symptoms, with partial remission of symptoms. Autism is a complex neurodevelopmental disorder with unknown etiology. Several factors have been postulated to be the cause including genetic factors, metabolic factors and certain types of infections, environmental factors as well as autoimmunity. Cell therapy has a potential to serve as a promising treatment for autism. The literature supports the therapeutic value of stem cells: unique self-renewal multilineage differentiation capabilities that could be harnessed for therapeutic purposes. In autism, various mechanisms are known to be responsible for causing disruption of the blood brain barrier. Also, these cells can home in to the damaged areas by forming new synaptic connections and strengthen the existing ones by a multi-disciplinary approach. [3–7]. Along with the major mechanisms implicated in the neuropathology of autism, neural hypoperfusion and immune abnormalities seem to be broadly consistent [8–10]. We administered autologous BMMNCs along with rehabilitation in a case with autism and monitored its effects for 6 mo. Significant improvement was noted consistently; both clinically as well as concurrently on the outcome measures. The BMMNCs were comprised of a variety of cells, which included mesenchymal stem cells (MSCs), hematopoietic stem cells, tissue specific progenitor cells and stromal cells. MSCs have an ability to modulate the immune system and restore the altered brain mechanism with a unique property of homing, wherein the cells migrate to the

site of injury and carry out the repair process [11]. The various stem cells enhance angiogenesis by producing signaling molecules such as vascular endothelial growth factor and fibroblast growth factor. Stem cells also promote tissue remodeling, prevent apoptosis, decrease inflammation and activate the satellite cells [12]. These cells have been postulated to activate the resident cells and carry out the repair process through neuronal regeneration or by secretion of cytokines and other biomolecules. The cells were injected intrathecally by a minimally invasive procedure. In our case, we hypothesize that these cells stimulate angiogenesis and may reverse the perfusion in the brain areas. This has been supported by a change in the metabolism of the brain as observed on PET scan, which showed a definite reduction in the standard deviation in the hippocampus, the right parahippocampus and in the mesial temporal lobes. These objective changes were found to correlate to the clinical improvements observed in the patient as put forth in Table 3 and Fig. 1.

The radiological metabolic improvements as observed on the repeat PE-CT images correlate with the clinical improvements seen in the areas of language comprehension, social interaction, improved projected action sequences, improved cognition and behavioral responses. As put forth in the table, there was a reduction in the standard deviation along with an increase in the SUV values in the parahippocampal and hippocampal regions, the cingulate and the paracingulate gyrus, the mesial temporal structures and the temporal lobe. This suggests improved metabolism and thereby suggests improved functioning in these areas leading to observed clinical improvements. The hippocampal and parahippocampal struc-

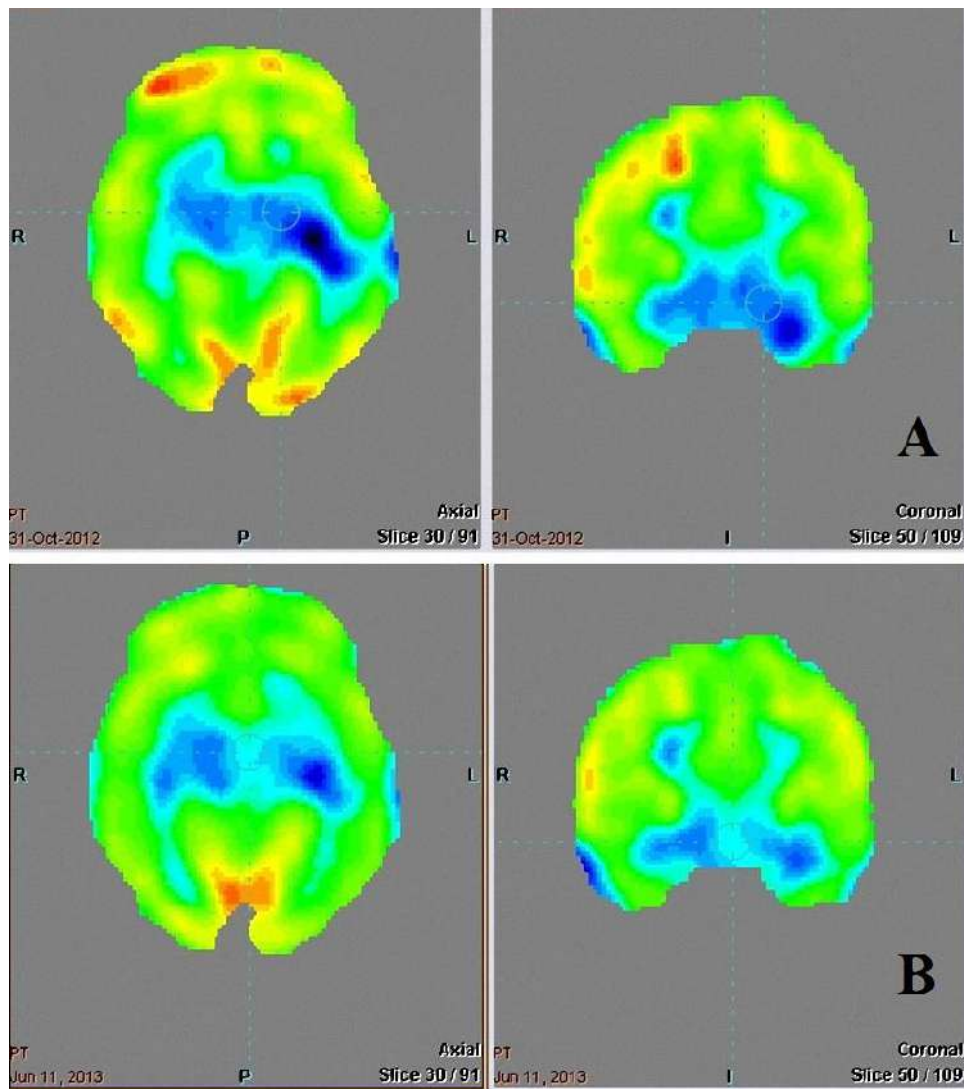


Fig. 1. Positron emission tomography computerized tomography images pre cell therapy (A) and 6 mo post cell therapy (B) showing an improved metabolism. The green color indicates normal standard uptake values, yellow and red means mildly raised and highly raised standard uptake values compared to normal. The blue areas (lesser than normal standard uptake values) indicate hypo-metabolism, which have reduced in the post cell therapy images explaining improvement in the standard uptake [(18)F]-fluoro-2-deoxy-D-glucose values. (Colours are visible in the online version of the article; <http://dx.doi.org/10.3233/JPN-140656>)

tures have been implicated in the processing of visuospatial and memory responses, which could have led to improved projected action sequence. Also, the cingulate regions and paracingulate gyrus regions showed a reduced standard deviation in the pre-cell therapy and post-cell therapy phases. The literature suggests that these areas have been involved in modulating behavior response and thus a change in these scores suggests an improvement in these areas [13,14]. The temporal lobe also shows a reduced standard deviation in the pre-cell and post-cell therapies, sug-

gesting a proposed improvement in language and comprehension skills. These improvements were found to be sustained on a 3 mo and 6 mo follow-ups and correlate with the CGI, ISAA, and functional independence measure scores remained the same indicating that there was no deterioration in the level of independence for ADLs after the cell therapy. However, it is noteworthy that there was an improvement in the ADL participation with respect to lesser verbal instructions required. Thus, the cell therapy effects portrayed on PET-CT scan of the brain

may help to serve as a new dimension for the management for autism. Through this single case study, the significant improvement noted clinically as well as radiologically can be expected to pave way for further exploration for new avenues of cell research in larger, randomized clinical trials.

In conclusion, our case study demonstrates that cell therapy method is safe, feasible and complements the conventional rehabilitation methods. It offers a new promise as an interventional modality that can be demonstrated objectively on PET-CT scan. Cell therapy in conjunction with comprehensive multidisciplinary rehabilitation can potentially pave the way for further clinical studies for effective functional outcomes. Larger, multicentric, randomized trials are required for detailed analysis.

## References

- [1] Courchesne E, Redcay E, Morgan JT, Kennedy DP. Autism at the beginning: microstructural and growth abnormalities underlying the cognitive and behavioral phenotype of autism. *Dev Psychopathol* 2005; 17(3): 577-97.
- [2] Horovitz M, Matson JL, Sipes M. The relationship between parents' first concerns and symptoms of autism spectrum disorders. *Dev Neurorehabil* 2011; 14(6): 372-7.
- [3] Baraniak PR, McDevitt TC. Stem cell paracrine actions and tissue regeneration. *Regen Med* 2010; 5(1): 121-43.
- [4] Siniscalco D, Giordano A, Galderisi U. Novel insights in basic and applied stem cell therapy. *J Cell Physiol* 2012; 227(5): 2283-6.
- [5] Sharma A, Gokulchandran N, Sane H, Nagrajan A, Paranjape A, Kulkarni P et al. Autologous bone marrow mononuclear cell therapy for autism: an open label proof of concept study. *Stem Cells Int* 2013; 2013: 623875.
- [6] Xu XL, Yi F, Pan HZ, Duan SL, Ding ZC, Yuan GH et al. Progress and prospects in stem cell therapy. *Acta Pharmacol Sin* 2013; 34(6): 741-6.
- [7] Sharma A, Gokulchandran N, Shetty A, Sane H, Kulkarni P, Badhe P. Autologous bone marrow mononuclear cells may be explored as a novel potential therapeutic option for autism. *J Clin Case Rep* 2013; 3(7): 282.
- [8] Capo LC. Autism, employment, and the role of occupational therapy. *Work* 2001; 16(3): 201-7.
- [9] Sykes M, Nikolic B. Treatment of severe autoimmune disease by stem-cell transplantation. *Nature* 2005; 435(7042): 620-7.
- [10] Ichim TE, Solano F, Glenn E, Morales F, Smith L, Zabrecky G et al. Stem cell therapy for autism. *J Transl Med* 2007; 5: 30.
- [11] Li L, Jiang J. Regulatory factors of mesenchymal stem cell migration into injured tissues and their signal transduction mechanisms. *Front Med* 2011; 5(1): 33-9.
- [12] Sharma A, Gokulchandran N, Chopra G, Kulkarni P, Lohia M, Badhe P et al. Administration of autologous bone marrow-derived mononuclear cells in children with incurable neurological disorders and injury is safe and improves their quality of life. *Cell Transplant* 2012; 21 Suppl 1: S79-90.
- [13] Brown JW, Braver TS. Learned predictions of error likelihood in the anterior cingulate cortex. *Science* 2005; 307(5712): 1118-21.
- [14] Yeung N, Nieuwenhuis S. Dissociating response conflict and error likelihood in anterior cingulate cortex. *J Neurosci* 2009; 29(46): 14506-10.